


* "PALFIQUE LX5" is sold in Japan under the name "ESTELITE Σ QUICK".

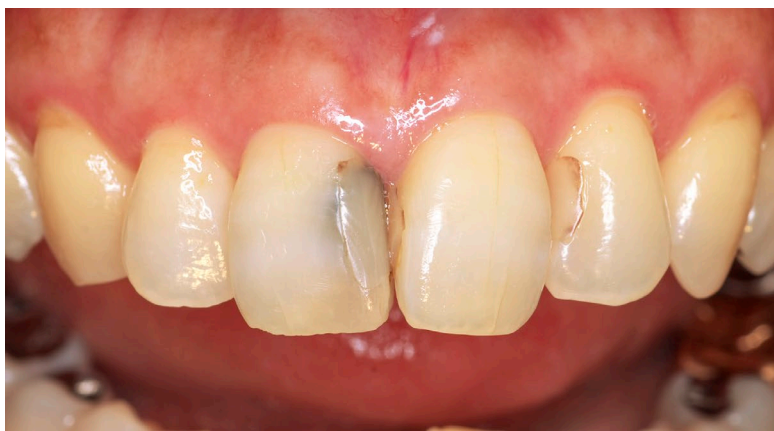Long-Term Clinical Case of Anterior Restoration

Dr. Shigehisa Inokoshi Private dental practice in Tokyo -Japan

ESTELITE SIGMA QUICK is a composite resin developed by Tokuyama Dental consisting mainly of Supra-Nano spherical fillers. It retains the basic structure of the first-generation ESTELITE launched in 1990, combined with an improved version of the polymerization catalyst. For 35 years, from the launch of the first ESTELITE version until today, the author has used this product exclusively as an aesthetic filling material. This report demonstrates that after 15 years this product still exhibits excellent color tone stability and gloss retention.



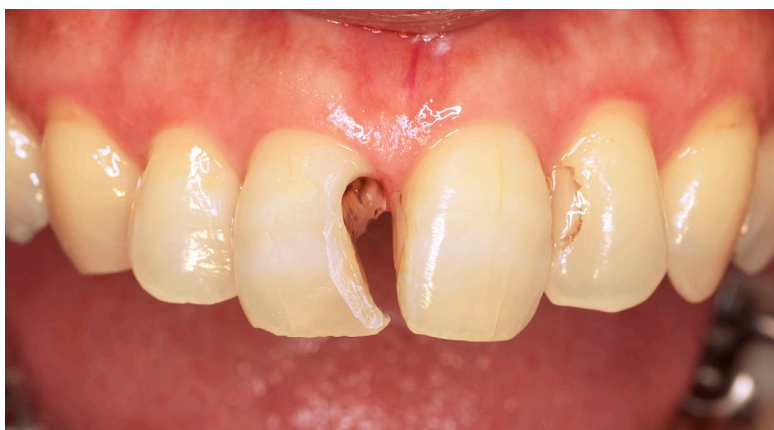The silica-zirconia filler spheres, which are the product's main component, are smaller than the wavelengths of the visible spectrum (about 0.4-0.7 μm), which gives it its exceptional polishability and gloss retention. Hardening this filler with resin and mixing it as an organic composite filler reduces the paste's stickiness during filling and allows for better handling. In addition, the multiple reflections of light occurring at the interface between the spherical and composite fillers with the matrix resin helps diffuse the margin line between the material and the tooth structure. This effect contributes to Tokuyama Dental's unique and unprecedented shade-matching property known as "self color matching." This product is expected to maintain its top position as aesthetic restoration material.



Before procedure. September, 14, 2009

Female (59 years old): Chief complaint of discoloration of the maxillary anterior teeth.

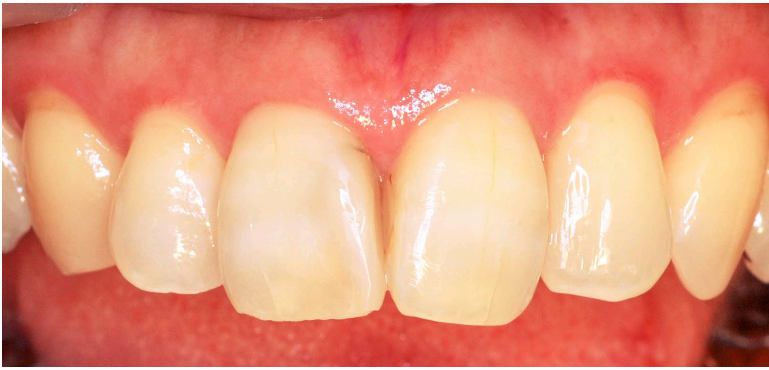A large Class III CR filling was present at the mesial proximal surface of #11, and secondary caries was noted on the cervical side of the tooth, probably due to microleakage. Class III CR filling was also present at the mesial proximal surface of #21 and #22, and a discolored line was seen along the margins.



After cavity preparation.

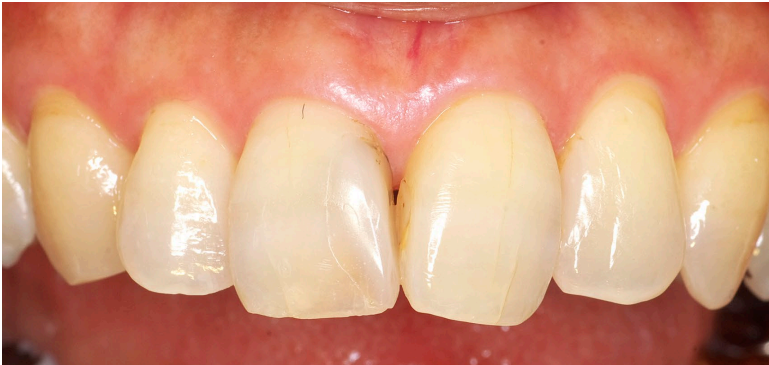The conventional restoration of the mesial proximal surface of #11 was removed, and further carious dentin was removed under the guidance of a caries detector. The dark discoloration observed on the cervical area exhibited a hard surface and did not stain with caries detector; it was left intentionally to avoid extending the cervical margin into the subgingival area.

A wide bevel was attached to the labial margin. The composite resin of the mesial part of #21 was polished again removing the discoloration at the labial margin as much as possible.



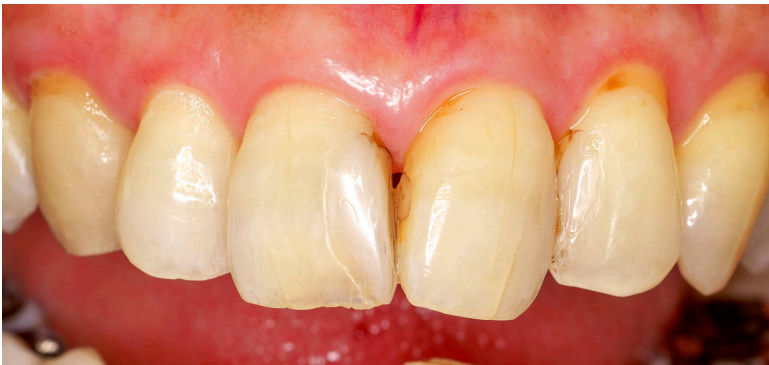After final polishing.

The mesial part of #11 was filled with ESTELITE SIGMA QUICK (A2) and final polishing was performed on November 2, 2009. At the same time, the previous CR filling in #22 mesial part was removed and the area also filled with ESTELITE SIGMA QUICK (A2), with polishing performed the same day.



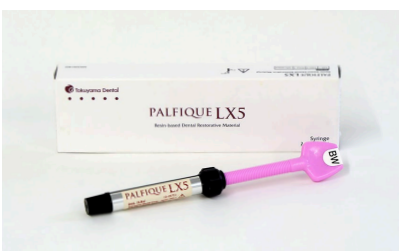After 5 years.

On October 24, 2014, 5 years later, the filling surface was polished again. The luster of the filling in both #11 and #22 was maintained without any discoloration.



After 15 years.

On December 14, 2024, 15 years later, the filling surface was polished again. Some discoloration is observed at the cervical margins of #11 and #22 which is difficult to reach with the polishing tools, but the luster of the filling material surface is maintained without discoloration.



PALFIQUE LX5

Syringe Refill

Contents: 1 syringe 2.0mL (3.8g)

Available shades: A1, A2, A3, A3.5, A4, A5, B1, B2, B3, B4, C1, C2, C3, OA1, OA2, OA3, OPA2, BW (Bleach White), WE (White Enamel), CE (Clear Enamel), SW (Snow White)

PLT Refill

Contents: 20 PLTs (0.2g each)

Available shades: A1, A2, A3, A3.5, A4, A5, B1, B2, B3, B4, C1, C2, C3, OA1, OA2, OA3, OPA2, BW (Bleach White), WE (White Enamel), CE (Clear Enamel), SW (Snow White)

Tokuyama Dental Corporation

38-9, Taitou 1-chome, Taitou-ku, Tokyo 110-0016, Japan

Tel: +81-3-3835-7201

URL: <https://www.tokuyama-dental.com/>